

## Laparoscopic Adrenalectomy for Adrenal Masses: Does Size Matter?

Octavio A. Castillo, Gonzalo Vitagliano, Fernando P. Secin, Marcelo Kerkebe, and Leonardo Arellano

<b>OBJECTIVES</b>	To examine the impact of adrenal tumor size on perioperative morbidity and postoperative outcomes in patients undergoing laparoscopic adrenalectomy.
<b>METHODS</b>	A total of 227 laparoscopic adrenalectomies were divided in three groups according to size as estimated by pathologic specimen maximum diameter: less than 6 cm (group 1, n = 140), between 6 and 7.9 cm (group 2, n = 47), and equal to or larger than 8 cm (group 3, n = 40). We prospectively recorded and analyzed clinical and pathologic data.
<b>RESULTS</b>	Average operative time was 60 minutes (range, 50 to 90 minutes) for group 1, 75 minutes (range, 65 to 105 minutes) for group 2, and 80 minutes (range, 65 to 120 minutes) for group 3. Estimated blood loss, median (interquartile range) was 50 mL (range, 20 to 100 mL), 100 mL (range, 48 to 225 mL), and 100 mL (range, 50 to 475 mL) for groups 1, 2, and 3, respectively. We observed a total of 10, 4, and 4 complications in groups 1, 2, and 3, respectively. Average hospital stay was 2 days (range, 2 to 3 days), 2 days (range, 2 to 3 days), and 3 days (range, 2 to 4 days), respectively, for groups 1, 2, and 3. Operative time, average blood loss, and mean hospital stay were significantly higher ( $P \leq 0.05$ ) for group 3 compared with group 1.
<b>CONCLUSIONS</b>	Laparoscopic adrenalectomy in large adrenal masses (8 cm or greater) is associated with significantly longer operative time, increased blood loss, and longer hospital stay, without affecting perioperative morbidity. UROLOGY 71: 1138–1141, 2008. © 2008 Elsevier Inc.

Ever since its first description by Gagner<sup>1</sup> in 1992, there have been multiple reports providing evidence of the benefits of laparoscopic adrenalectomy based on decreased bleeding, diminished postoperative pain, less hospital stay, and faster convalescence.<sup>2–8</sup> Present indications for laparoscopic adrenalectomy include various pathological states such as aldosteronoma, pheochromocytoma, Cushing's disease, nonfunctioning adenomas, and rare entities such as cysts and myelolipomas.<sup>2</sup> However, controversy persists on the use of laparoscopic adrenalectomy for the management of malignant adrenal masses, particularly when they measure over 5 to 6 cm in diameter, invade adjacent organs (liver, kidney, or pancreas), or have associated vein thrombus.<sup>3,6,8,9</sup> Centers with high laparoscopic experience make of tumor size a relative contraindication to the laparoscopic approach.<sup>5,10,11</sup>

The inability of radiological imaging to differentiate malignant from benign lesions accurately has resulted in the persistent use of size as an indicator of malignant

potential, considering tumors larger than 5 cm to be at high risk for malignancy.<sup>10</sup>

Our objective was to examine the impact of adrenal tumor size (less than 6 cm versus 6 to 7.9 cm versus 8 cm or greater) on perioperative morbidity and postoperative outcomes in our series of patients undergoing laparoscopic adrenalectomy.

### MATERIAL AND METHODS

Between June 1993 and January 2006, a single surgeon (O.A.C.) performed 227 laparoscopic adrenalectomies in 205 patients. Demographic, clinical, pathologic, intraoperative, postoperative, and follow-up data were prospectively collected and compared among the 3 groups. Groups were generated according to size as estimated by pathologic specimen maximum diameter: less than 6 cm (group 1, n = 140), between 6 and 7.9 cm (group 2, n = 47), and equal to or larger than 8 cm (group 3, n = 40). The size criteria were elected based on prior reports.<sup>3,5,12</sup>

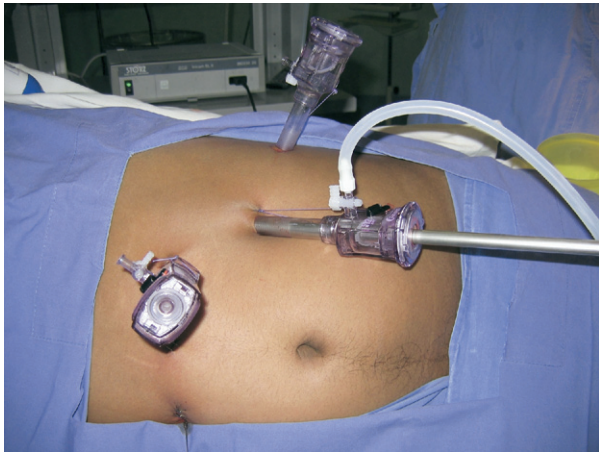
### Surgical Technique

This technique was developed during the learning curve of a single, self-taught laparoscopist. The same technique was employed in all cases independent of size. All procedures were carried out transperitoneally and trocar position varied according to tumor side. On the left, three trocars were placed 3 cm below the costal rim: a 10-mm trocar on the midaxillary line for

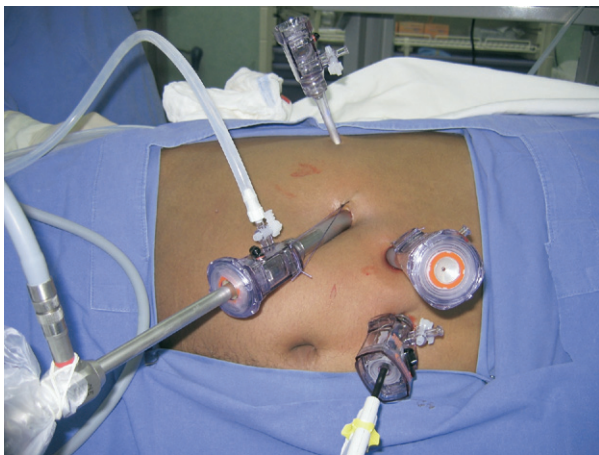
From the Section of Endourology and Laparoscopic Urology, Clínica Santa María, and the Departments of Urology and Human Pathology, School of Medicine, Universidad de Chile, Santiago de Chile, Chile; and the CEMIC University Hospital, Buenos Aires, Argentina

Reprint requests: Dr. Octavio Castillo, Section of Endourology and Laparoscopic Urology, Department of Urology, Clínica Santa María, Avenida Santa María 0500, 7530234 Providencia, Santiago de Chile. E-mail: octaviocastillo@utr.net

Submitted: June 7, 2007, accepted (with revisions): December 4, 2007



**Figure 1.** Trocar placement for left adrenalectomy.



**Figure 2.** Trocar placement for right adrenalectomy.

the camera, a second 10-mm trocar on the posterior axillary line, and a third 5-mm trocar on the median clavicular line (Fig. 1). We initially divided the splenocolic ligament and reflected the splenic angle of the colon. The spleen and the tail of the pancreas were mobilized medially to expose the adrenal gland.

On the right side, a fourth 5-mm trocar was added in the epigastrium to insert a liver retractor (Fig. 2). Prior sectioning of the triangular hepatic ligament facilitated liver retraction. Toldt's line was subsequently dissected caudally to expose the upper pole of the kidney and the inferior vena cava.

Once the adrenal gland had been exposed, adrenal vessels were identified, clipped, and divided. The specimen was finally extracted in a laparoscopic bag.

Complications were classified as intraoperative, postoperative, or delayed. Intraoperative complications were classified using the system proposed by Vallancien *et al.*<sup>13</sup> according to the degree of severity: major—life-threatening or requiring a stay of more than 24 hours in the intensive care unit and reoperation; intermediate—requiring reoperation, conversion, or admission to the intensive care unit for less than 24 hours; and minor—did not require admission to the intensive care unit, reoperation, or prolongation of hospitalization. Postoperative complications included any adverse event occurring

within 30 days of surgery, whereas delayed complication was defined as any event occurring after a month of surgery.

### Statistical Methods

We calculated exact confidence intervals for the overall incidence of complications. We used one-way analysis of variance (ANOVA) test to compare numeric variables among the 3 groups, whereas we compared categorical variables using pairwise Chi-square tests. A nominal level of 5% statistical significance was assumed. Statistical analyses were conducted using Stata 8.2 (Stata Corp., College Station, Tex).

### RESULTS

Table 1 summarizes demographic and operative data of the three groups. The median patient age in the series was 52 years (interquartile range [IQR], 38 to 63) and the male-to-female ratio was 1:1.6. Incidental diagnosis was performed in 50%, 44%, and 50%, respectively, for groups 1, 2, and 3. Median (IQR) maximum specimen diameter was 3.5 cm (range, 2.8 to 4.5 cm), 6.5 cm (range, 6 to 7 cm), and 9.3 cm (range, 8 to 11 cm) for groups 1, 2, and 3, respectively. A total of 87 (38%) of the 227 adrenalectomies were performed on tumors measuring over 6 cm in maximum diameter. Median (IQR) operative time was 60 minutes (range, 50 to 90 minutes) for group 1, 75 minutes (range, 65 to 105 minutes) for group 2, and 80 minutes (range, 65 to 120 minutes) for group 3. Estimated blood loss, median (IQR) was 50 mL (range, 20 to 100 mL), 100 mL (range, 48 to 225 mL), and 100 mL (range, 50 to 475 mL) for groups 1, 2, and 3, respectively. By ANOVA, operative time and estimated blood loss were significantly higher for group 3 compared with group 1 (Table 1).

We observed a total of 10 complications (7%) in group 1, 5 of which were minor intraoperative complications: 2 renal vein tears and 1 spleen and 2 diaphragmatic injuries, respectively, all successfully managed intraoperatively by means of intracorporeal suture. One patient presented severe intraoperative hemorrhage (over 500 mL). Two patients had postoperative complications: 1 case of hyponatremia which did not require extension of length of hospital stay and 1 pancreatic fistula which was managed with percutaneous drainage and subsequent endoscopic papillotomy. We observed delayed incisional hernias in 3 patients (2.5%).

We observed 4 complications (9%) in group 2. There was 1 major intraoperative complication: a hypertensive crisis leading to death in a patient operated on for a 7-cm right adrenal pheochromocytoma. The patient received standard 2-week preoperative preparation with  $\alpha$ - and  $\beta$ -blockers and surgery was performed with minimal adrenal gland manipulation. We observed intraoperative intermediate level complications in 2 patients, 1 severe intraoperative hemorrhage that required conversion to open surgery and blood transfusion, and 1 diaphragmatic injury that was successfully sutured laparoscopically. One patient was diagnosed with a retroperitoneal hematoma postoperatively and successfully managed expectantly.

**Table 1.** Demographic and operative data of the three groups

	Laparoscopic Adrenalectomy for Masses < 6 cm (n = 140)	Laparoscopic Adrenalectomy for Masses 6–7.9 cm (n = 47)	Laparoscopic Adrenalectomy for Masses > 8 cm (n = 40)	P-Value
Mean age, median (IQR)	54 (44–64)	47 (35–61)	46 (31–57)	1 vs 3, 0.02; 2 vs 3, 1 and 1 vs 2, 0.2
Male gender	43% (33)	18% (46)	18% (49)	0.12
Side: right	47% (67)	57% (27)	40% (16)	0.3
Incidental diagnosis	50%	44%	50%	0.8
Size, median cm (IQR)	3.5 (2.8–4.5)	6.5 (6–7)	9.3 (8–11)	<0.001 among all groups
Operative time, median min (IQR)	60 (50–90)	75 (65–105)	80 (65–120)	1 vs 3, 0.004; 2 vs 3, 0.2 and 1 vs 2, 0.9
No. of complications	10 (7%)	4 (9%)	4 (10%)	0.7
Intraoperative				
Major	0	1 (%) Death	0	
Intermediate	0	2	0	
Minor	5	0	3	
Postoperative				
Delayed	2	1	1	
No. of conversions	3	0	0	
No. of conversions	0	1	0	0.9
Estimated blood loss, mL (IQR)	50 (20–100)	100 (48–225)	100 (50–475)	1 vs 3 0.005; 2 vs 3, 0.3 and 1 vs 2, 1
Transfusion, n (%)	4 (3)	1 (2)	3 (8)	0.3
Mean hospital stay, days (IQR)	2 (2–3)	2 (2–3)	3 (2–4)	1 vs 3, 0.02; 2 vs 3, 0.6 and 1 vs 2, 0.7
Malignant tumor (ACC and metastasis) n (%)	16 (12)	9 (19)	13 (33)	1 vs 3, 0.004; 2 vs 3, 0.2 and 1 vs 2, 0.6

ACC = adrenocortical carcinoma; IQR = interquartile range.

A total of 4 complications (10%) occurred in group 3. We observed minor intraoperative complications in 3 patients, 2 patients presented with significant intraoperative bleeding (over 500 mL), and 1 patient had a diaphragmatic injury that was successfully repaired laparoscopically. One patient had a postoperative retroperitoneal hematoma that was expectantly managed. A total of 3 patients (8%) received a blood transfusion. There were no delayed complications in this group.

Median (IQR) hospital stay was 2 days (range, 2 to 3 days), 2 days (range, 2 to 3 days), and 3 days (range, 2 to 4 days), respectively, for groups 1, 2, and 3. Hospital stay was significantly higher for group 3 ( $P < 0.02$ ) compared with group 1 (Table 1).

## DISCUSSION

Many authors have demonstrated a significant decrease in perioperative morbidity and convalescence for laparoscopic adrenalectomy compared with open surgery. In 1988, Winfield *et al.*<sup>3</sup> published a comparative study of 21 and 17 patients who underwent laparoscopic and open adrenalectomy, respectively. The authors found an initial advantage in operative time in favor of open surgery, which later diminished as the learning curve of the laparoscopic technique was surpassed. A relevant advantage was also found in favor of laparoscopic adrenalectomy with regard to return to a complete diet, analgesic requirements, hospital stay, and convalescence ( $P < 0.001$ ). Although there was no significant difference

in tumor size between groups (laparoscopic, 1.8 cm; and classic open surgery, 2.5 cm;  $P = 0.196$ ), the authors suggested leaving the laparoscopic approach for adrenal lesions under 6 cm that had no evidence of malignancy or multifocality. Similar findings and recommendations have been reported by other authors.<sup>6,8,9</sup>

Motivated by the significant advantages of laparoscopy over classic surgery, several authors have extended the inclusion criteria of this technique. Gill,<sup>2</sup> in a broad revision of laparoscopic adrenalectomy, remarked that even though adrenal mass size is not an irrefutable contraindication to the laparoscopic technique, it is generally not feasible for tumors over 10 to 12 cm owing to the increase incidence of malignancy. Gagner *et al.*<sup>5</sup> and Assalia and Gagner<sup>12</sup> considered laparoscopic adrenalectomy to be the procedure of choice in adrenal surgical pathology, except in the setting of carcinoma or in masses over 15 cm. Because of the increased risk of malignancy in lesions over 6 to 8 cm, Assalia and Gagner also advocated limiting laparoscopic adrenalectomy to lesions under 8 cm.

In 2000, Hobart *et al.*<sup>10</sup> published a study comparing a group of 14 patients submitted to laparoscopic adrenalectomy for masses greater than 5 cm (group I) with other two groups of patients: group II, corresponding to 14 patients submitted to open adrenalectomy for masses greater than 5 cm, and a third group of 45 patients submitted to laparoscopic adrenalectomy for masses less than 5 cm (group III). They found that laparoscopic adrenalectomy could be performed safely and in a rea-

sonable time, either transperitoneally or retroperitoneally for adrenal masses under and over 5 cm (groups III and I). Contrary to what was observed with open adrenalectomy for large tumors, laparoscopic adrenalectomy for large adrenal masses allows for early diet, short hospital stay with less convalescence, and better cosmetic results. However, in group I a greater rate of conversion to open surgery was found, as opposed to the laparoscopic adrenalectomy group for small masses: 12.2% versus 2.1%, respectively.

Recently Novitsky *et al.*<sup>11</sup> published a series of 24 consecutive laparoscopic adrenalectomies in patients with adrenal masses over 5 cm. Mean mass diameter was 6.8 cm, with a mean operative time of 178 minutes (range, 120 to 300 minutes). No conversions to open surgery were reported. The authors also found that the advantages classically advocated for laparoscopic adrenalectomy were maintained despite the increase in mass size. This is the biggest series of laparoscopic adrenalectomies for large adrenal masses published. However, the concerns about laparoscopic removal of large adrenal tumors are justifiable by the higher malignant potential of these lesions and the inherent risk of capsular disruption and tumor spillage.

In our series, we compared 140 laparoscopic adrenalectomies for adrenal masses under 6 cm with 47 performed for masses between 6 and 8 cm and 40 of performed for masses of 8 cm or larger. There was a statistically significant difference ( $P < 0.05$ ) in blood loss and operative time for group 3; however, no difference was observed between groups 1 and 2.

We observed 10, 4, and 4 of complications in groups 1, 2, and 3, respectively. There was no significant difference in the number of perioperative complications in all groups ( $P = 0.7$ ). This could be explained by the fact that larger adrenal tumors were performed later in the series after the surgeon had mastered the technique. When the severity of intraoperative complications is compared, it is clear that complications are similar among all groups. The only death reported in our series involved a patient who underwent laparoscopic adrenalectomy for a 7-cm right adrenal pheochromocytoma (group 2). Despite a standard preoperative preparation, the patient suffered an uncontrollable hypertensive crisis leading to intraoperative death. Nevertheless, we have continued performing this technique for all pheochromocytomas obtaining excellent results. Larger adrenal masses may require prolonged dissection and this could be associated with increased operative bleeding, however; the number of perioperative complications is similar in all groups. This would indicate that laparoscopic adrenalectomy for large adrenal masses, while technically demanding, is feasible without additional morbidity.

Median (IQR) hospital stay was 2, 2, and 3 days for groups 1, 2, and 3, respectively. There was a statistically significant difference ( $P < 0.05$ ) for group 3. The increased operative bleeding and time recorded in group 3 may account for the longer hospital stay. However, this is comparable to other series of laparoscopic adrenalectomies indicating that, despite the considerable size of the adrenal masses, the advantages of the laparoscopic approach persist.

Despite our results, transperitoneal laparoscopic adrenalectomy may not be the best choice for all large adrenal masses. Concomitant pathology such as hostile abdomen from multiple prior surgeries, extension into contiguous organs, or presence of inferior vena cava thrombus may call for retroperitoneoscopy or even an open approach.

## CONCLUSIONS

Laparoscopic adrenalectomy of large adrenal masses (8 cm or greater) is associated with significantly longer operating time, increased blood loss, and longer hospital stay. However, it may be performed by experienced surgeons without significantly affecting perioperative morbidity.

## References

1. Gagner M, Lacroix A, and Bolte E: Laparoscopic adrenalectomy in Cushing's syndrome and pheochromocytoma. *N Engl J Med* **327**: 1033-1036, 1992.
2. Gill IS: The case for laparoscopic adrenalectomy. *J Urol* **166**: 429-436, 2001.
3. Winfield HN, Hamilton BD, Bravo EL, *et al*: Laparoscopic adrenalectomy: the preferred choice? A comparison to open adrenalectomy. *J Urol* **160**: 325-329, 1998.
4. Gill IS, Hobart MG, Schweizer D, *et al*: Outpatient adrenalectomy. *J Urol* **163**: 717-719, 2000.
5. Gagner M, Pomp A, Heniford BT, *et al*: Laparoscopic adrenalectomy: lessons learned from 100 consecutive procedures. *Ann Surg* **226**: 238-247, 1997.
6. Hazzan D, Shiloni E, and Goliljanin D: Laparoscopic vs open adrenalectomy for benign adrenal neoplasm: a comparative study. *Surg Endosc* **15**: 1356-1358, 2001.
7. Brunt LM, Doherty GM, and Norton JA: Laparoscopic adrenalectomy compared to open adrenalectomy for benign adrenal neoplasms. *J Am Coll Surg* **183**: 1-10, 1996.
8. Korman JE, Ho T, and Hiatt JR: Comparison of laparoscopic and open adrenalectomy. *Am Surg* **63**: 908-912, 1997.
9. Barresi RV, and Prinz RA: Laparoscopic adrenalectomy. *Arch Surg* **143**: 212-217, 1999.
10. Hobart MG, Gill IS, Schweizer D, *et al*: Laparoscopic adrenalectomy for large-volume ( $\geq 5$  cm) adrenal masses. *J Endourol* **14**: 149-154, 2000.
11. Novitsky YW, Czerniach DR, Kercher KW, *et al*: Feasibility of laparoscopic adrenalectomy for large adrenal masses. *Surg Laparosc Endosc Percut Techniques* **13**: 106-110, 2003.
12. Assalia A, and Gagner M: Laparoscopic adrenalectomy. *Br J Surg* **91**: 1259-1274, 2004.
13. Vallancien G, Cathelineau X, Baumert H, *et al*: Complications of transperitoneal laparoscopic surgery in urology: review of 1,311 procedures at a single center. *J Urol* **168**: 23-26, 2002.