

Laparoscopic Retrieval of a Migrated Amplatz Sheath

Octavio A. Castillo, MD, Esteban Metrebian, MD, Gonzalo Vitagliano, MD

ABSTRACT

Objectives: Percutaneous nephrolithotomy is a relatively safe technique. However, it is not exempt from complications, some of which can be severe and even fatal. Some complications may be plausible for laparoscopic management. We report our experience in the management of a rare complication by laparoscopic means.

Methods: We report the case of an Amplatz sheath that inadvertently migrated out of the renal parenchyma during a percutaneous nephrolithotomy. Patient data, procedure conditions, and laparoscopic retrieval of the sheath are detailed.

Results: The Amplatz sheath was successfully retrieved laparoscopically. Total operative time was 180 minutes. Operative bleeding was minimal. The postoperative period was uneventful, and the patient was discharged on postoperative day 3.

Conclusions: Laparoscopy must be regarded as an option for the management of a surgical complication, especially if a minimally invasive approach is to be kept.

Key Words: Laparoscopy, Percutaneous nephrolithotomy, Amplatz, Complications.

INTRODUCTION

In 1955, Goodwin and coworkers¹ first presented their experience with “percutaneous trocar (needle) nephrostomy in hydronephrosis.” Initially, percutaneous nephrostomy was used only for urinary diversion, but later it became the prelude to more complex procedures, such as stone extraction. Since then, percutaneous renal surgery has dramatically evolved. Multiple pathologies, such as pyeloureteral obstruction, calyceal diverticula, and even transitional cell carcinoma may be treated through this approach.

A percutaneous approach for treating staghorn calculi has significantly diminished the morbidity of this pathology in comparison with the classic open approach. Due to technological advances, percutaneous nephrolithotomy has become a relatively safe procedure. However, this technique is not exempt from complications, some of which can be severe and even fatal. With the widespread use of percutaneous techniques, the potential for complications associated with this approach may increase.^{1,2} Complications of nephrolithotomy can occur while percutaneous access creation, calculi treatment, or during the postoperative period. Usually, these complications correspond to excessive bleeding, pneumothorax, hemothorax, neighboring organ lesion, and infection.^{1,3-6}

Nevertheless, other less frequent complications can occur and may warrant a specific treatment.⁷⁻¹¹ To this regard, laparoscopy has become a versatile tool that may allow for less morbid management.

We report the case of a dislodged Amplatz sheath that was retrieved using a laparoscopic approach. Patient data and procedure conditions are detailed.

CASE REPORT

A healthy, 38-year-old, male patient was seen for acute right lumbar pain. Radiological findings showed significant hydronephrosis with a 2-cm calculus impacted on the right ureteropelvic junction (UPJ). Body mass index was 31.4 kg/m².

A percutaneous nephrolithotomy with the patient under general anesthesia was carried out. The patient was

Section of Endourology and Laparoscopic Urology, Department of Urology, Clínica Santa María, Santiago de Chile, Chile (all authors).

Department of Urology, School of Medicine, Universidad de Chile, Santiago de Chile, Chile (Dr Castillo).

Address reprint requests to: Octavio Castillo, Section of Endourology and Laparoscopic Urology, Department of Urology, Clínica Santa María, Avda Santa María 0500 7530234 Providencia, Santiago de Chile, Chile. E-mail: octavio.castillo@vtr.net

© 2007 by JSL. *Journal of the Society of Laparoendoscopic Surgeons*. Published by the Society of Laparoendoscopic Surgeons, Inc.

placed in a supine position. The inferior calyceal system was punctured and progressively dilated until a 28 Fr Amplatz sheath was placed. The calculus was fragmented by pneumatic lithotripsy, and fragments were extracted using a trident grasper. During the procedure, the Amplatz sheath was practically buried in the subcutaneous tissue. While reintroducing the nephroscope, the guidewire was inadvertently withdrawn and the percutaneous access was lost. Fluoroscopy showed that the Amplatz sheath had migrated medially and was out of reach (**Figure 1**). After several attempts at percutaneous recovery of the sheath were unsuccessful, laparoscopic retrieval of the migrated Amplatz sheath was decided upon.

Surgical Technique

The patient was placed in a lateral left flank decubitus position. A 15-mm Hg pneumoperitoneum was created using a Veress needle. Three access ports were placed, a 10-mm umbilical port for the camera, another 10-mm trocar in the midaxillary line 2 cm below the costal margin, and a 5-mm trocar 2 cm above the iliac crest in line with the other port. The abdominal cavity was carefully explored, finding only a small retroperitoneal hematoma. The right ascending colon was totally mobilized from the cecum up to the hepatic flexure. The Amplatz sheath was found between the duodenum and the inferior vena cava (**Figure 2**). No vascular or bowel injuries were observed. The Amplatz sheath was extracted through a 10-mm ac-

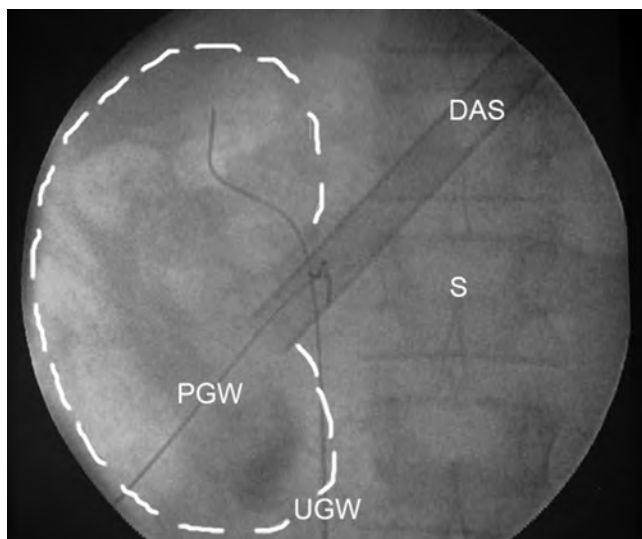


Figure 1. Fluoroscopy showing the dislodged Amplatz sheath (DAS), ureteral guidewire (UGW), percutaneous guidewire (PGW), and spine (S).

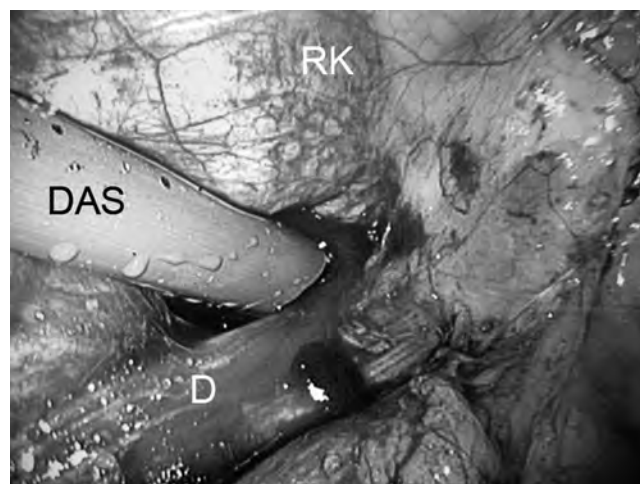


Figure 2. Dislodged Amplatz sheath (DAS) found between the duodenum (D) and the inferior vena cava.

cess port incision. Neither abdominal suction tubes nor a nephrostomy were left in place.

RESULTS

Total operative time, including percutaneous lithotripsy, was 180 minutes. Laparoscopic retrieval of the lost sheath only took 35 minutes. Operative bleeding was minimal. Recovery was without incident, and the patient was discharged on postoperative day 3. Follow-up has been uneventful and the patient remains stone free.

DISCUSSION

Percutaneous nephrolithotomy is a minimally invasive technique for renal calculi treatment. However, it is not exempt from complications. Uncontrolled bleeding and infection leading to sepsis are mostly feared.³⁻⁶ However, less common occurrences, such as thromboembolic complications, nephropleural fistulas, migration of a dislodged tip of an ultrasound lithotripter probe, retention of a nephrostomy thread, and even a rupture renal sheath have been reported.⁷⁻¹¹ Some of these complications may be plausible for laparoscopic management to preserve a minimally invasive approach.

We report herein an Amplatz sheath becoming dislodged when the guidewire was inadvertently withdrawn and the sheath unintentionally shoved into the subcutaneous tissue. Multiple intents to retrieve it percutaneously were futile. To minimize morbidity, laparoscopy was used to explore the abdominal cavity and the retroperitoneum. The sheath was successfully retrieved by laparoscopic means.

Laparoscopy has previously been used to assist percutaneous nephrolithotomy of pelvic kidneys.¹² Due to their position, these kidneys cannot be accessed through the flank approach routinely used. Moreover, laparoscopy has been recently used as an aid to transperitoneal percutaneous nephrolithotomy for ectopic and horseshoe kidneys.^{13,14} Also the management of anterior calyceal diverticula has been performed using a combined approach.¹⁵ However, we believe this is the first report of the management of this rare occurrence by means of laparoscopy.

CONCLUSION

Laparoscopy is an effective technique for abdominal and retroperitoneal exploration. The laparoscopic approach may be used in the management of surgical complications, especially when a minimally invasive approach is to be preserved.

References:

1. McDougall E. Percutaneous approaches to the upper urinary tract. In: Walsh, PC, ed. *Campbell's Urology*. 8th ed. Philadelphia, PA: Saunders; 2002.
2. Valdivia Uria JG, Valle Gerhold J, Lopez Lopez JA, et al. Technique and complications of percutaneous nephroscopy: experience with 557 patients in the supine position. *J Urol*. 1998;160:1975–1978.
3. Lee WJ, Smith AD, Cubelli V, et al. Complications of percutaneous nephrolithotomy. *AJR*. 1987;148(1):177–180.
4. Gremio E, Ballanger P, Dore B, Aubert J. Hemorrhagic complications during percutaneous nephrolithotomy. Retrospective study of 772 cases. *Prog Urol*. 1999;9(3):460–463.
5. Srivastava A, Singh KJ, Suri A, et al. Vascular complications after percutaneous nephrolithotomy: are there any predictive factors? *Urology*. 2005;66(1):38–40.
6. Holman E, Salah MA, Toth C. Comparison of 150 simultaneous bilateral and 300 unilateral percutaneous nephrolithotomies. *J Endourol*. 2002;16(1):33–36.
7. Patel A, Fuchs G. Air travel and thromboembolic complications after percutaneous nephrolithotomy for staghorn stone. *J Endourol*. 1998;12(1):51–53.
8. Lin CH, Chen CH, Tzeng WS, Cheng BC, Chiu AW. Migration of dislodged tip of an ultrasound lithotripter probe to the pulmonary artery: a rare complication of percutaneous nephrolithotomy. *Urology*. 2003;62(6):1121–1122.
9. Ahn J, Trost DW, Topham SL, Sos TA. Retained nephrostomy thread providing a nidus for atypical renal calcification. *Br J Radiol*. 1997;70:309–310.
10. Lallas CD, Delvecchio FC, Evans BR, Silverstein AD, Preminger GM, Auge BK. Management of nephropleural fistula after supracostal percutaneous nephrolithotomy. *Urology*. 2004;64(2):241–245.
11. Ugras M, Gunes A, Baydinc C. Severe renal bleeding caused by a ruptured renal sheath: case report of a rare complication of percutaneous nephrolithotomy. *BMC Urol*. 2002;2:10–16.
12. Troxel SA, Low RK, Das S. Extraperitoneal laparoscopy-assisted percutaneous nephrolithotomy in a left pelvic kidney. *J Endourol*. 2002;16(9):655–657.
13. Maheshwari PN, Bhandarkar DS, Andankar MG, Shah RS. Laparoscopically guided transperitoneal percutaneous nephrolithotomy for calculi in pelvic ectopic kidneys. *Surg Endosc*. 2004;18(7):1151.
14. Maheshwari PN, Bhandarkar DS, Shah RS, Andankar MG, Saple AL. Laparoscopy-assisted transperitoneal percutaneous nephrolithotomy for recurrent calculus in isthmic calix of horseshoe kidney. *J Endourol*. 2004;18(9):858–861.
15. Brunet P, Meria P, Mahe P, Danjou P. Laparoscopically-assisted percutaneous nephrolithotomy for the treatment of anterior calyceal diverticula. *BJU Int*. 2000;86(9):1088–1089.